

Abington, Monica

Follicular Survey 12/2/2007

Preliminary Info, Indications

Name: Abington, Monica	Exam Date: 12/2/2007	Indications:
Patient ID: 123456789	Procedure: Follicular Survey	Infertility
DOB: 12/2/1971	Exam Site: Inpatient	
Age: 36 yrs	Insurance: Humana	
Ref. Phys: Martinez, David, M.D.		

Ovaries

Left Ovary

Doppler

Length: 5 cm **Max:** 0.544m/s **PI:** 1.64
Width: 3 cm **Min:** 0.122m/s **RI:** 0.74
Height: 4 cm **TAMX:** 0.244m/s **S/D:** 4.1
Volume: 16.8 cc

Size: Normal

Right Ovary

Doppler

Length: 5 cm **Max:** 0.534m/s **PI:** 1.66
Width: 3 cm **Min:** 0.120m/s **RI:** 0.76
Height: 2 cm **TAMX:** 0.242m/s **S/D:** 4.2
Volume: 16 cc

Size: Normal

Follicles

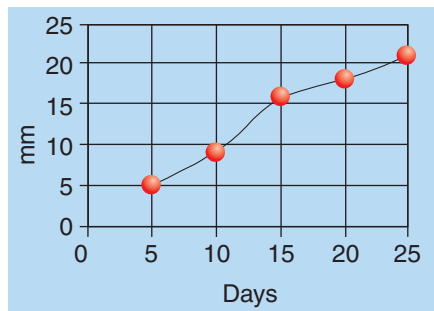
Left Ovary

Follicle #	Length(mm)	Width(mm)	Height(mm)	Volume(mm ³)
1.	21	20	15	331
2.	11	11	12	76
3.	9	12	10	57
4.	10	9	7	33

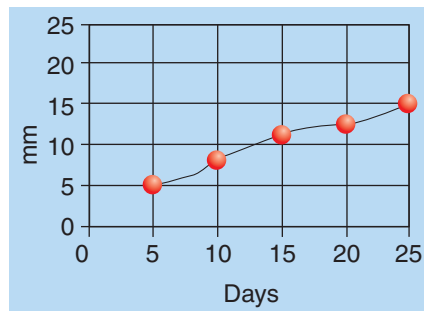
Right Ovary

Follicle #	Length(mm)	Width(mm)	Height(mm)	Volume(mm ³)
1.	15	12	8	753
2.	10	8	4	167
3.	6	5	3	47
4.	4	2	2	8

Left Ovary: Dominant Follicle, #1



Right Ovary: Dominant Follicle, #1



Peter Dale, M.D.

Sonographer: Sally Sonographer, RDMS

Thank You For This Referral