

## Abington, Monica

## Follicular Survey 12/2/2006

### Preliminary Info, Indications

<b>Name:</b> Abington, Monica	<b>Exam Date:</b> 12/2/2006	<b>Indications:</b>
<b>Patient ID:</b> 123456789	<b>Procedure:</b> Follicular Survey	Infertility
<b>DOB:</b> 12/2/1971	<b>Exam Site:</b> Inpatient	
<b>Age:</b> 35 yrs	<b>Insurance:</b> Humana	
<b>Ref. Phys:</b> Martinez, David, M.D.		

### Ovaries

Left Ovary	Doppler	Right Ovary	Doppler
<b>Length:</b> 5 cm	<b>Max:</b> 0.544m/s <b>PI:</b> 1.64	<b>Length:</b> 5 cm	<b>Max:</b> 0.534m/s <b>PI:</b> 1.66
<b>Width:</b> 3 cm	<b>Min:</b> 0.122m/s <b>RI:</b> 0.74	<b>Width:</b> 3 cm	<b>Min:</b> 0.120m/s <b>RI:</b> 0.76
<b>Height:</b> 4 cm	<b>TAMX:</b> 0.244m/s <b>S/D:</b> 4.1	<b>Height:</b> 2 cm	<b>TAMX:</b> 0.242m/s <b>S/D:</b> 4.2
<b>Volume:</b> 16.8 cc		<b>Volume:</b> 16 cc	
<b>Size:</b> Normal		<b>Size:</b> Normal	

### Follicles

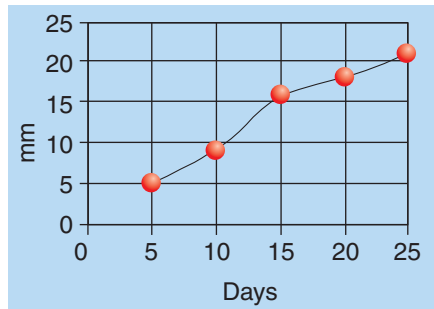
#### Left Ovary

Follicle #	Length(mm)	Width(mm)	Height(mm)	Volume(mm <sup>3</sup> )
1.	21	20	15	331
2.	11	11	12	76
3.	9	12	10	57
4.	10	9	7	33

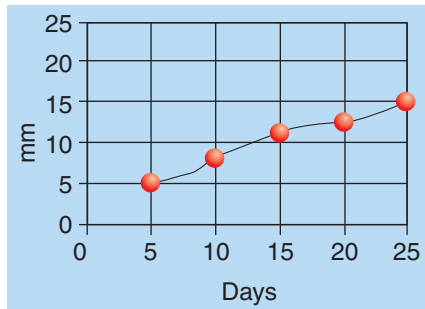
#### Right Ovary

Follicle #	Length(mm)	Width(mm)	Height(mm)	Volume(mm <sup>3</sup> )
1.	15	12	8	753
2.	10	8	4	167
3.	6	5	3	47
4.	4	2	2	8

#### Left Ovary: Dominant Follicle, #1



#### Right Ovary: Dominant Follicle, #1



**Peter Dale, M.D.**

*Sonographer: Sally Sonographer, RDMS*

Thank You For This Referral