

[back to main page](#)

[back to filter fields](#)

Query Results

[Step 1: Choose Fields](#) | [Step 2: Filter Fields](#) | **Step 3: View Results**

Results: 1-25 of 647 | [Next 25 >>](#)

View: [Compact](#) | [Expanded](#)

[Check All](#)

Send Checked to...

[New Folder]

Query Criteria:

- Patient ID
- First Name
- Last Name
- Date of Birth (DOB)

[View Exam](#)
[View Images](#)

Query Options:

Export Options:

- Checked
- Printable Report
- Export to Text
- Export to Excel
- Export to SPSS

	Patient ID	First Name	Last Name	DOB
<input type="checkbox"/> 1.	test2	Tanya	Twins	10/16/1977
<input type="checkbox"/> 2.	x000006526	TIFFANY	Testpatient	6/16/1972
<input type="checkbox"/> 3.	x000006614	Vicki	Testpatient	7/14/1958

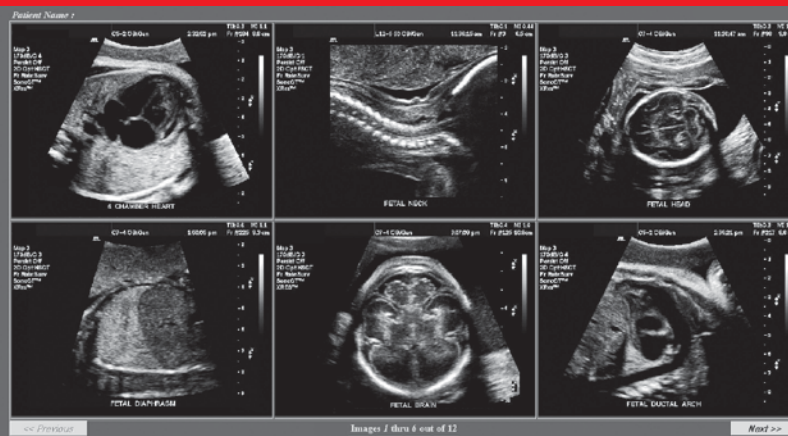
Comments:

...FOSSA.. THE **CARDIAC** OUTFLOW TRACTS WERE INCOMPLETELY VISUALIZED DUE TO FETAL POSITION. BIOPHYSICAL PROFILE FETAL PRESENTATION IS VERTEX. BPP WAS PERFORMED FOLLOWING A NON-REACTIVE NST. NST IS REACTIVE WITH (A NORMAL BASELINE ...

Comments:

...SYNDROME. AN **ACARDIAC** TWIN IS SEEN. OLIGOHYDRAMNIOS/POLYHYDRAMNIOS SEQUENCE IS SEEN, CONSISTENT WITH TWIN-TWIN TRANSFUSION SYNDROME 6/29/2005 DAVID A. MARTINEZ, MD 944 MARKET ST. SAM FRANCISCO, CA 94102 ...

View Images



ECHOCARDIOGRAM WAS DOPPLER, AND COLOR ... MALLY ORIENTED WITHIN ... RE IDENTIFIED. THE ...

ent 12/12/1982

ECHOCARDIOGRAM WAS DOPPLER, AND COLOR ... MALLY ORIENTED WITHIN ... RE IDENTIFIED. THE ...

ent 12/14/1974

CTILITY APPEARS NORMAL. ... D. THE TRICUSPID VALVE IS ... CUSHIONS ARE SEEN. THE ... HE ATRIAL SEPTUM AND ...

Lynette Testpatient 2/11/1966

D. FETAL **CARDIAC** PULSATION OR **CARDIAC** ACTIVITY IS ... THE FETAL HEART RATE IS 103 BPM. THE CERVIX IS ... LEFT OVARY MEASURES 2.3 CM X 1.9 CM X 1.8 CM. THE ... IS NOT VISUALIZED. RETURN ...

Heidi Testpatient 7/28/1977

F **CARDIAC** ANOMALY. A FETAL ECHOCARDIOGRAM WAS ... USING 2-D, M-MODE, PULSED DOPPLER, AND COLOR ... NG. THE FETAL HEART IS NORMALLY ORIENTED WITHIN ... TEST. ALL FOUR CHAMBERS WERE IDENTIFIED. THE ...

View Exam Report

CLICKVIEW Corporation
944 Market Street, Suite 402
San Francisco, CA 94102
800 628 0020
415 693 9494 fax

Twins, Tanya D.

Exam Date: 5/10/2008

Patient ID: test2
Ref Phys: Martinez, David M.D.
DOB: 10/16/1977
Age: 30
OBHx: G:(2) F Trm:(0) Pre:(0) Ab-I:(0)
Ab-S:(0) Ect:(0) Multi:(0) Liv:(1)

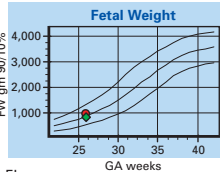
Procedure: Obstetrical Ultrasound
Exam Site:
Plurality: 2
Fetus: A
LMP: 11/9/2004

Measurements: [cm, wks]

GS:
CRL:
BPD: 6.5 26w2d [±1.36]
FL: 4.9 26w3d [±1.28]
AC: 25 27w1d [±1.23]
HC: 22.2 26w4d [±1.31]
HL: 4.4 26w2d
TCD: 2.4 23w0d

Best Sono Method: BPD, HC, AC, FL
Best Sono GA: 26w1d [±1.02]

Selected GA:
GA: 26w0d
Method: EDD
EDD: 8/16/2005



Best Sono Method: BPD, HC, AC, FL
Best Sono GA: 26w1d [±1.02]

Selected FW:
Gms: 968
%: 56%
Method: BPD, AC, HC, FL